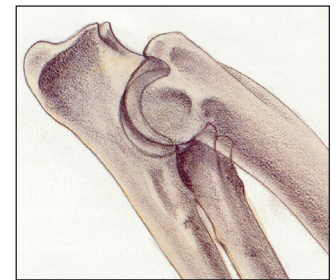
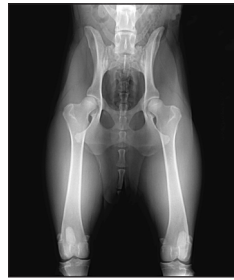



# Instructions for Taking Images for OFA Dysplasia Evaluations

## Images should be permanently identified with:

1. Registered name and/or number
  2. Name of veterinarian or hospital making the film
  3. Date image taken
- Pelvic evaluation are based on the standard VD view with good pelvic definition, pelvis not tilted and femurs extended and parallel
  - Elbow evaluations are based on the extreme flexed medial to lateral view



## OFA Database

The dysplasia control database of the OFA is a voluntary program established to evaluate images and to identify films showing no evidence of dysplasia or other orthopedic problems. All images submitted that are of acceptable diagnostic quality will be reviewed by qualified veterinary radiologists and a consensus report will be returned to the owner of record and referring veterinarian. Only animals that are 24 months of age or older to the day at the time of radiography, with no radiographic evidence of dysplasia, will be assigned a breed OFA number. The OFA does offer a consultation service for those under 24 months of age.

## Age Requirement

Only dogs that are 24 months of age, to the day, or older at the time of radiography can qualify for an OFA hip number. In general hip joint status of younger dogs will be evaluated but only a consultation report will be issued. For toy and small breeds interested in the Legg-Calve-Perthes Database the animal has to be 12 months of age or older. The dog's registration certificate or copy of this information should be available at the time of radiography.

## OFA Policy Regarding Release Of Preliminary Results (Animals Under 24 Months)

In an effort to encourage open sharing of health test results, the OFA will post preliminary results if:

- The animal is at least 12 months at the time of radiography
- The animal must be permanently identified via microchip or tattoo
- The owner initials the authorization block to release all results (including abnormal results) when the application is initially submitted

## Restraint

Obtaining proper position often requires chemical restraint. The OFA recommends chemical restraint to the point of muscular relaxation. The type of agent used—sedative, tranquilizer, or general anesthesia—is best determined by the attending veterinarian.

## Positioning

Dorsal recumbency with the rear legs **extended and parallel** to each other is the preferred positioning. This standard ventrodorsal view is the basis for evaluation of hip joint status with respect to hip dysplasia. Care should be exercised to be sure the pelvis is not tilted. Elbow joints are evaluated in the fully flexed medial to lateral position.

## Image Size

For large and giant breeds of dogs, 14" x 17" film size is recommended. Smaller sizes can be used for smaller breeds if the area between the sacrum and the stifles can be included.

## Image Identification

Permanent identification of the image is required to be eligible for OFA evaluation. Lead letters, an I.D. camera, or radio opaque tapes can be used to identify film. Digital images should have embedded text.

- (a) with the hospital or Veterinarian's name, date taken, registered name and/or registration number or
  - (b) with the veterinarian's unique case number.
- In this latter case (b), the image must be accompanied by a signed note from the veterinarian referring to such film by its unique case number and stating the information previously required in (a) above.
  - If the above required information is illegible or missing, the OFA cannot accept the film for evaluation purposes. The images should be labeled right or left side for hip studies and right or left elbow for elbow studies.

## Exposure

Good contrast is desirable (high mAs, low kVp). Grid techniques are recommended for all large dogs.

## Radiation Safety

Proper collimation and protection of attendants is the responsibility of the veterinarian. Gonadal shielding is recommended for male dogs.

## Hormonal Effect

Some female dogs show subluxation when radiographed around an estrus cycle which is not apparent when re-radiographed in anestrus. The OFA recommends radiographing 3-4 weeks before or after a heat period or 3-4 weeks after weaning a litter of pups.

## Application for OFA Film Evaluation

The owner or agent must complete and sign the OFA application form. This information is best obtained directly from the dog's certificate of registration and **it is recommended that a copy of the registration be included** with the submission. Application forms are available on request from the OFA and from the OFA website at [www.offa.org](http://www.offa.org). The **image, signed form, and service fee** should be mailed together to the Orthopedic Foundation for Animals at the address on the front of this form.